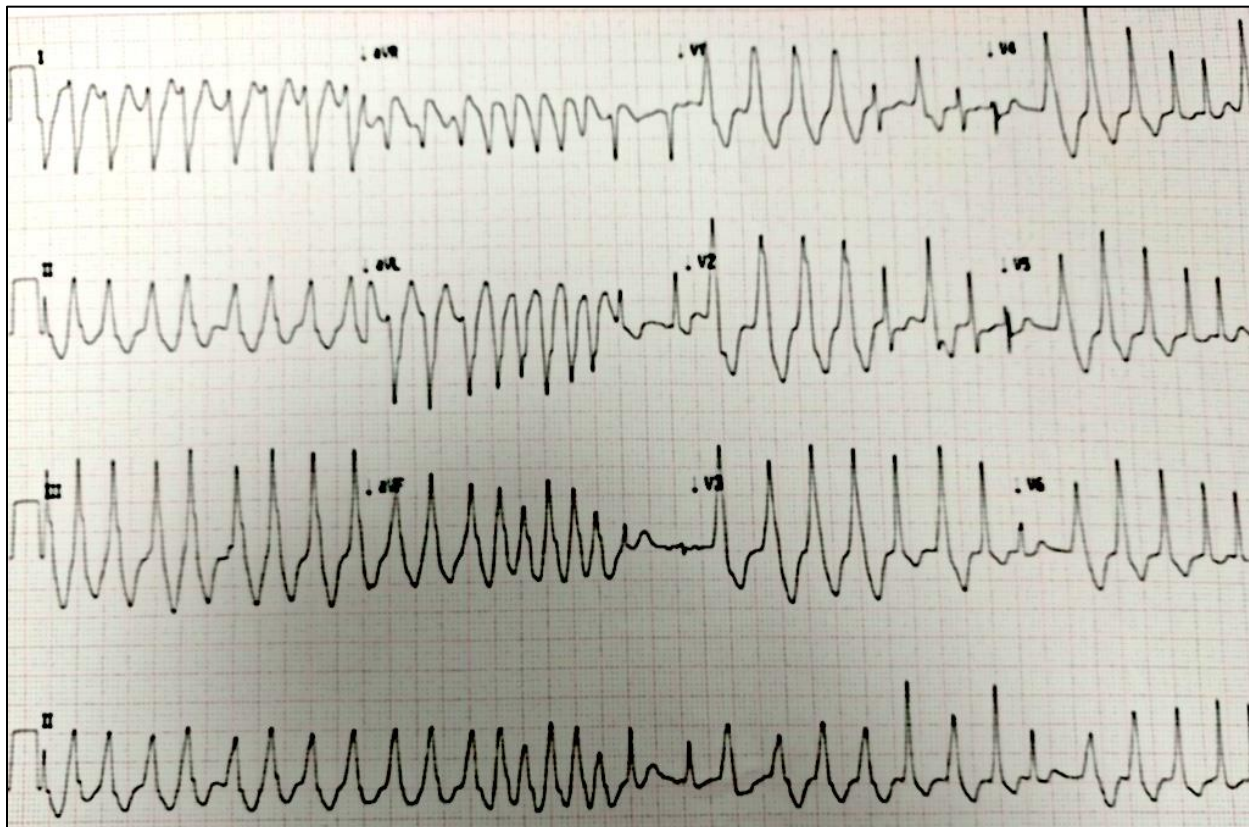


#1 – 29 yo F p/w palpitations



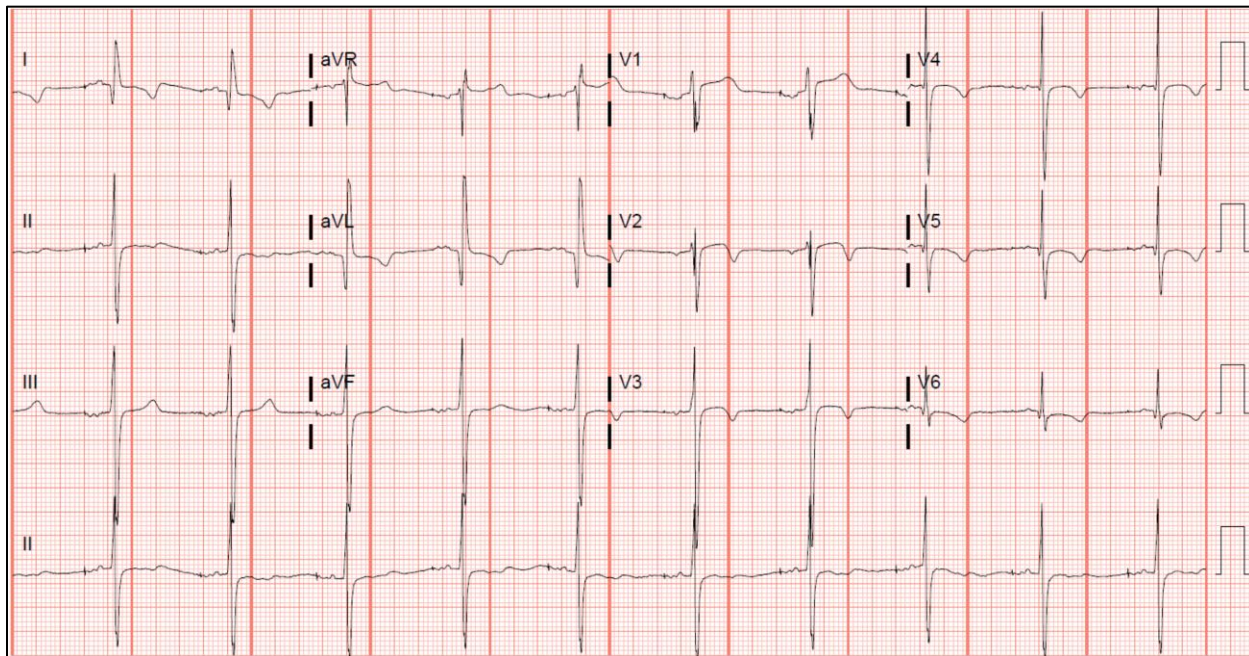
Rate: _____ Rhythm: _____ Axis: _____ Intervals: _____ Ischemia: _____

What triad of findings would you expect to see on this patient's baseline resting ECG?

Assuming this patient is stable, what is the next best step in management?

What type of medications should be avoided?

#2 – 43 yo M p/w syncope



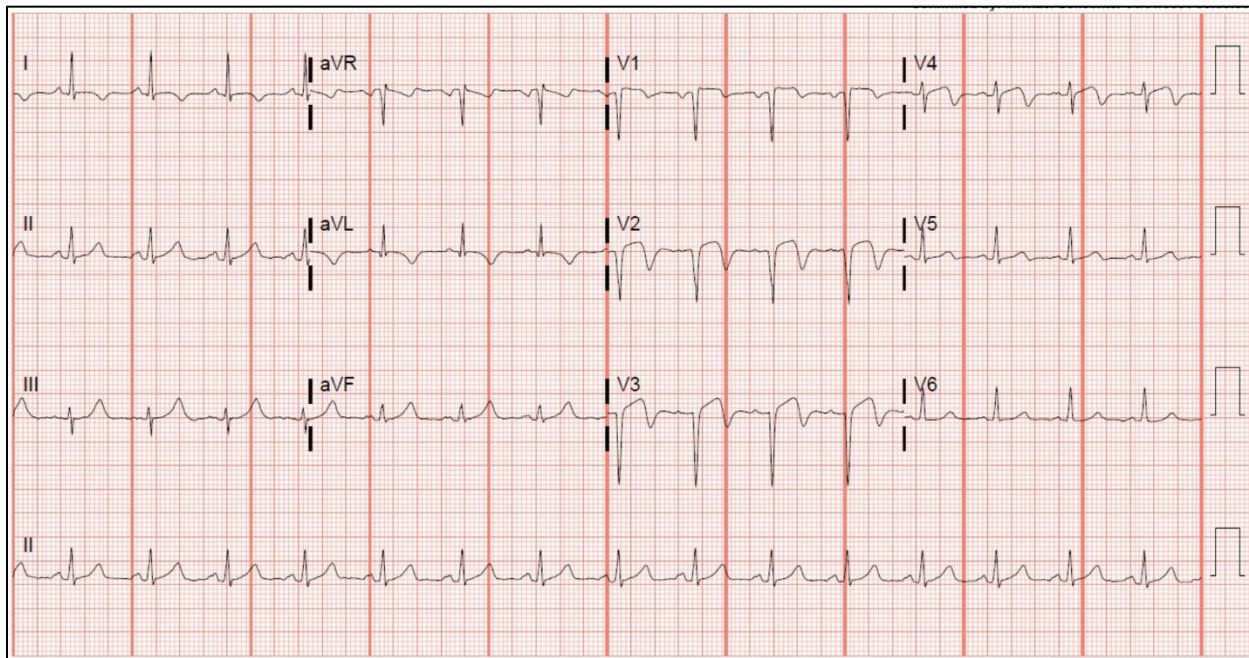
Rate: _____ Rhythm: _____ Axis: _____ Intervals: _____ Ischemia: _____

What electrocardiographic and physical exam finding suggests the diagnosis?

What are the treatment options?

What is the disposition for this patient?

#3 – 53 yo M p/w CP, currently CP-free

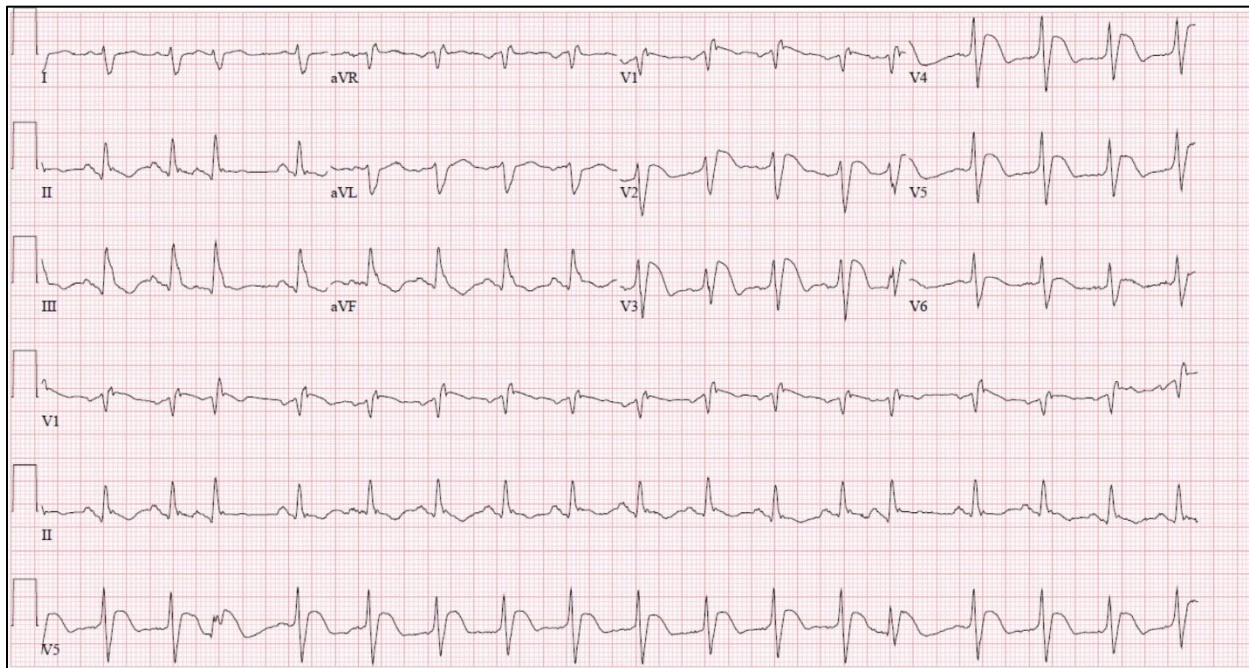


Rate: _____ Rhythm: _____ Axis: _____ Intervals: _____ Ischemia: _____

Would you activate the cath lab for this ECG?

What are the critical actions in the ED?

#4 – 67 yo M p/w CP

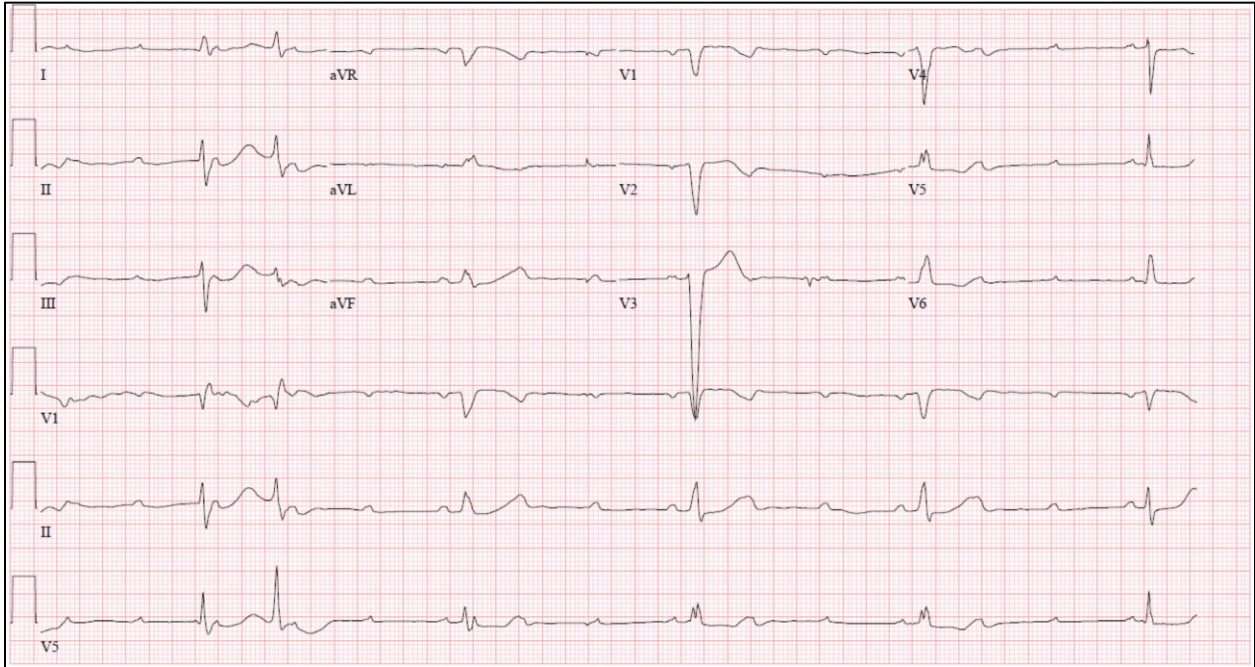


Rate: _____ Rhythm: _____ Axis: _____ Intervals: _____ Ischemia: _____

Would you activate the cath lab for this ECG?

What findings suggest a poorer prognosis?

#5 – What's the rhythm?



Rate: _____ Rhythm: _____ Axis: _____ Intervals: _____ Ischemia: _____